

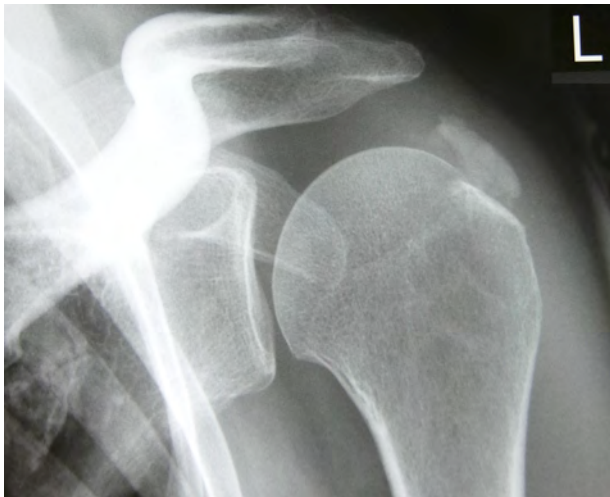
## Case 2

### Ms R. K., 46 yrs old, periarthritis humero-scapularis

Ms K. consults us for sharp throbbing pain in her left shoulder, which gradually started three months ago. It has now developed into a severe acute condition after sport. She can hardly move her left arm and in particular has trouble raising it. Touch is very painful and she has numbness in fingers IV and V of the left hand. The pain has prevented her from sleeping at all for the last two nights.

On examination we find a very sensitive swelling with excessive warmth and reddening in front of the left shoulder joint. Extreme, painful limitation of movement. No other findings.

Blood test, C-reactive protein (CRP) and rheumatism serology are normal. The most probable diagnosis is periarthritis humero-scapularis, which is confirmed on x-ray (fig. 1).



**Fig. 1: Left shoulder, before treatment**

Finding: *extensive periarthritis humero-scapularis calcarea with areas of coarse, granular calcification in the area of the supraspinatus tendon. Arthrosis of the acromioclavicular (AC) joint, otherwise the joint condition is normal.*

Using the *Checklist for Acute Illness: Musculoskeletal System*, Ms K. noted the following symptoms:

- Touch: worse (P)
- External pressure: worse (P)
- Cold in general: better (P)
- Wrapping up warmly: worse (P)
- Physical exercise: worse (P)
- Raising affected limb: worse (P)
- Sitting: worse (P)
- Standing: better (P)
- Movement: worse (P)
- Initial movement: worse

(P) = polar symptoms

During the discussion she says that the pain is so severe that she can no longer work as a teacher. She finds it agonising to perform everyday tasks.

The initial repertorisation uses only the polar symptoms.

### Repertorisation (*Boenninghausen's Therapeutic Pocketbook 2000*)

	Led.	Rhus.	Nux-v.	Bry.	Calc.	Phos.	Borx.	Chin.	Merc.	Nit-ac.	Thuj.	Ign.	Lyc.
Number of hits	9	9	9	9	9	9	9	9	9	9	9	9	8
Sum of grades	21	19	19	19	18	17	15	15	15	15	12	10	25
<b>Polarity difference</b>	<b>15</b>	<b>0</b>	<b>4</b>	<b>5</b>	<b>4</b>	<b>4</b>	<b>6</b>	<b>6</b>	<b>4</b>	<b>11</b>	<b>-2</b>	<b>-5</b>	<b>15</b>
< touch (p) [121]	3	3	4	3	1	1	2	1	2	3	1	1	4
< pressure, external (p) [93]	2	1	1	1	3	2	1	1	2	3	1	1	4
> cold in general (p) [73]	3	1	1	1	1	1	1	1	1	1	2	1	2
< warmly, from wrapping up (p) [37]	1	1	1	1	3	2	3	2	1	1	2	2	4
< physical effort (p) [70]	1	4	3	4	3	2	1	3*	2	2	1	1	5*
< raising affected limb (p) [60]	3	3	1	2	1	1	1	1	1	1	1	1	1
< sitting (p) [126]	1	4	1	1	2*	1	2	2	1	1	2	1	4
> standing (p) [71]	3	1	3	2	2	4*	2	1	2	1	1	1	
< movement, during (p) [126]	4	1	4	4	2	3	2	3*	3	2	1	1	1
> touch (p) [42]				2	4/CI	3/CI		1			3/CI		1
> pressure, external (p) [74]	1	3/CI	2	2	1	1	3/CI	1	1		2	2	
< cold in general (p) [90]	1	4/CI	4/CI	2	1	2	3/CI	2	1	1	1	3/CI	1
> warmly, from wrapping up (p) [56]	1	4/CI	3/CI	1		1	1	2	2		1	1	
> physical effort (p) [6]												3/CI	
> raising affected limb (p) [27]			1		4/CI	2					2	2	2
> sitting (p) [101]	2	1	4/CI	4/CI	2	2	2	1	3/CI	1	1	1	
< standing (p) [107]	1	3/CI	1	2	1	1		1	1	1	2	2	2
> movement, during (p) [102]		4/CI		1	1	1		1	3	1	2	1	4/CI

Key: < = worse, > = better, (P) = polar symptom, [121] = number of remedies matching the symptom (e.g. < touch). CI = Contraindication. Remedies with contraindications are shown with a grey background. See case 1 for the definition of a contraindication and how to calculate the polarity difference.

Twelve remedies cover all relevant symptoms but only three have no contraindications: *Ledum*, *Nitricum acidum* and *China*. *Ledum*, with the highest polarity difference, best fits the patient's symptoms. *Nitricum acidum* is the second best whereas *China* only has a coincidental correlation.

### **Materia medica comparison for *Ledum*** (Clarke, vol. 5, p. 2923)

**Extremities:** Affects mainly the left shoulder and right hip. Lancinating pains in shoulder, on raising or moving arms. Aching pain in joints of shoulder, and of elbow, < by movement.

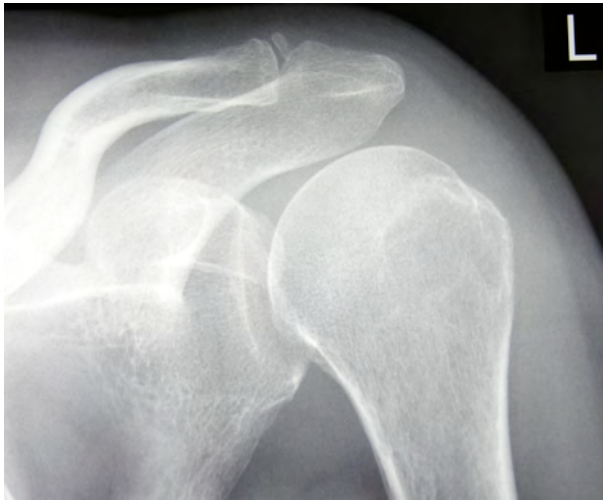**General:** Tearing or shooting, pulsative and paralytic pains in joints, < by movement. Numbness and sensation of torpor in several of the extremities. Gouty nodosities in joints. Hard, hot, tense swellings, with tearing pains.

The materia medica entry for *Nitricum acidum* is nothing like as relevant to this case.

### **Remedy and Prescription**

Ms K. is given a dose of *Ledum 200 C*. She rings the next day to say that she slept well and that she can move her arm more easily. The next day she feels worse again after having to adopt a painful

posture for the x-ray. *Ledum 500 C* now produces an improvement of 50-70% for four days. Then the pains become worse again. *Ledum 1000 C* improves the pains by 70-80% for 10 days. She can now fully raise her arm and is pain-free for periods. Due to the short duration of action for the single doses, we decide to change to daily doses of liquid *Ledum Q3*. A month later Ms K. only has pain with specific movements: she rates the improvement as 80%. We continue with increasing doses of *Ledum in Q potencies*. Three months after the start of treatment, she is fully pain-free and can move her left shoulder almost normally. Eight months after the start of treatment, her symptoms have completely disappeared. The current x-ray shows the following finding (fig. 2).



**Fig. 2: Left shoulder eight months after the start of homeopathic treatment**

*Complete remission of the calcium deposits seen on Dec 8, 2004. Minor arthrosis of AC joint, otherwise the condition of the joint is normal.*