

Treatment of Chronic Idiopathic Thrombocytopenic Purpura with Homeopathic Dilutions of Patient Blood

Behandlung der chronischen idiopathischen thrombocytopenischen Purpura mit homöopathischen Verdünnungen des Patientenblutes.

Short Title

ITP treatment with potentiated patientblood
ITP-Behandlung mit potenziertem Patientenblut

Heiner Frei, MD

Institute of Complementary Medicine, University of Bern, Switzerland

Center for Integrative Pediatrics, Laupen, Switzerland

Contactinformation:

Heiner Frei, MD, Pediatrician FMH, Homeopathy SVHA

Kreuzplatz 6, CH-3177 Laupen, Switzerland

Email: heiner.frei@hin.ch

Tel: 0041 31 747 94 93

Fax: 0041 31 747 94 92

Abstract

Background: Chronic ITP is commonly regarded as an immunological disorder. Conventional and homeopathic treatment are often difficult. Imhäuser describes the use of homeopathic dilutions of patient blood for immunomodulation, which inspired us to try the method in an ITP- case.

Method: A two-year-old girl with chronic ITP has been treated with homeopathic dilutions of her own capillary blood (HPB), given orally over five months.

Result: Immediately after treatment onset there was a rapid normalization of the thrombocytes. Within six weeks they rose from 15,000/microliter to 254,000/microliter. After treatment stop they sank to 155,000/microliter, rerose spontaneously to 270,000/microliter and remained within normal range over three years.

Conclusion: Oral administration of homeopathic dilutions of capillary patient blood may possibly be an effective treatment in chronic ITP. If our result can be reproduced it would revolutionize ITP treatment.

Key Words:

Chronic ITP, Treatment, Homeopathic Dilutions of Patientblood

Zusammenfassung

Einführung: Die chronische ITP wird allgemein als immunologische Erkrankung betrachtet. Konventionelle und homöopathische Behandlung sind oft schwierig. Imhäuser hat die Verwendung von potenziertem Patientenblut zur Immunomodulation empfohlen, was uns veranlasste dies bei einer ITP-Patientin anzuwenden.

Methode: Ein zweijähriges Mädchen mit chronischer ITP wurde mit homöopathischen Verdünnungen ihres Kapillarblutes (HPB) oral während fünf Monaten behandelt.

Resultat: Unmittelbar, nach Behandlungsbeginn stieg die Thrombozytenkonzentration von 15000/Mikroliter auf 254000/Mikroliter an. Nach Therapieende sank sie auf 155000/Mikroliter, und pendelte sich schliesslich über drei Jahre bei Werten um 270000/Mikroliter ein.

Schlussfolgerung: Homöopathische Verdünnungen von patienteneigenem Kapillarblut sind möglicherweise eine effektive Behandlung für die chronische ITP. Kann die beobachtete Wirkung reproduziert werden, entspräche sie einer Revolution in der ITP-Behandlung.

Schlüsselwörter

Introduction

Chronic thrombocytopenic purpura (ITP) is an autoimmune disorder with antibodies against platelet membranes, resulting in platelet destruction and/or suppression of platelet production[1]. Several authors have observed that ITP in children occurs after infections with EBV, CMV or HIV, or in adults concomitant to helicobacter pylori infections. Although the pathogenesis is still unclear, a possible mechanism might be a cross-reaction of antimicrobial antibodies with platelet membranes. Typical symptoms of ITP such as mucocutaneous bleeding appear with platelet counts below 30,000/microliter. Platelet counts below 10,000/microliter may lead to epistaxis, menorrhagia and even life-threatening intracranial hemorrhage. The ITP incidence in Nordic countries is 4.8 cases per 100,000 children, and children with *insidious* onset are most likely to develop chronic disease[2]. Conventional treatment consists of glucocorticoids and immunoglobulins, which normally lead to a transient rise in platelet concentration. If severe bleeding has to be stopped, the patients may need platelet transfusions and even splenectomy. Rarely treatment with cytostatics is necessary to suppress autoantibody-producing cells.

In alternative medicine Gousta and Saberi reported a positive effect of individualized homeopathic remedies in the treatment of ITP[3], while our own experience with individualized homeopathy in chronic ITP is rather mixed. We therefore chose for our latest case (see below) another approach. *Imhäuser* describes in her book *Homöopathie in der kinderärztlichen Praxis (Homeopathy in Pediatric Practice)* a treatment with homeopathic dilutions of patient blood (HPB) for disturbances of the immunological system[4]. This is the method we used.

Methods

Laboratory examinations: The hematological tests were performed with a modern flow-cytometer which undergoes daily internal and several external quality controls per year.

Treatment: To obtain a homeopathic dilution of capillary patient blood (HPB), we use a disposable 50 microliter glass pipette. The blood is then diluted in 5 ml alcohol (30%) in a glass tube with cover. The next step is to vigorously shake the tube 10 times (ORG § 270) [5]. The result is a so-called 1C potency of HPB (abbreviated HPB 1C). This is further diluted with 30% alcohol by the pharmacy in steps of 1:100, each step concluded with 10 vigorous shakings, until the potencies HPB 7C (seven dilution steps), HPB 9C (nine dilution steps, etc.), HPB 12C and HPB 15C are obtained. The patient receives each potency in an 8ml bottle with pipette, and starts treatment with HPB 7C, 3 x 3 drops orally per day for four weeks, continuing with HPB 9C 3 drops a day for four weeks, then HPB 12C 3 drops twice a week for one month, and finally HPB 15C 3 drops once a week for the last month. The treatment can if necessary be continued with HPB 15C over a longer time.

Results in Pilot Patient

Two-year-old Debora (name changed) has been suffering from unusual hematomas with minor trauma throughout the summer season and increasingly severe during the last three months. In addition she is very pale and often tired, and her mother, who works as a psychologist in a University Childrens Hospital, fears that she might have acute leukemia. The examination reveals large hematomas on the legs, and smaller ones on the arms and face, all of differing ages. The size of the spleen is normal and there are no enlarged lymph nodes nor any other internal findings. The *blood examination* shows a hemoglobin level of 112 g/l, white blood count of 8.200/microliter, slight lymphocytosis (62.1%) and a platelet count of

28,000/microliter. Our diagnosis is *chronic thrombocytopenic purpura*, and Debora is referred to the University Childrens Hospital for further assessment. The hematologists confirm the diagnosis and send her back without treatment into our care. She comes two days later with new hematomas and a platelet count of 15,000/microliter.

Now we make a homeopathic dilution of her blood and begin treatment with HPB 7C. After two weeks the platelet count has risen to 105,000/microliter, and a month later under HPB 9C it reaches 254,000/microliter. All clinical symptoms disappear within four weeks after treatment start. The course of the platelet concentrations is shown in *figures 1 and 2*.

After five months the treatment is stopped. Within the next four weeks the platelet count sinks to 155,000/microliter (still within normal range), and then recovers spontaneously to levels around 270,000/microliter. This recovery has remained stable over the last three years. The treatment with HPB was well tolerated by the patient and had no side effects.

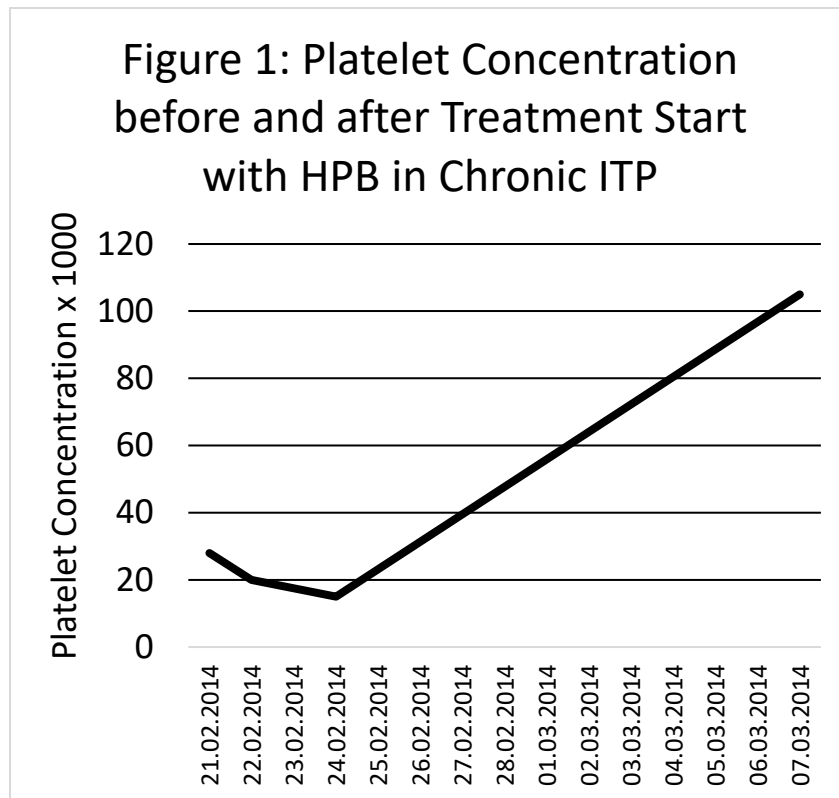


Figure 1: Platelet concentration in chronic ITP (x 1000/microliter) before and after treatment start with homeopathic dilutions of patient blood (HPB). The date treatment started is Feb. 24, 2014. Note the immediate increase in platelet concentration after the begin of HPB treatment. (Dates on the x-axis are in the format DD/MM/YYYY).

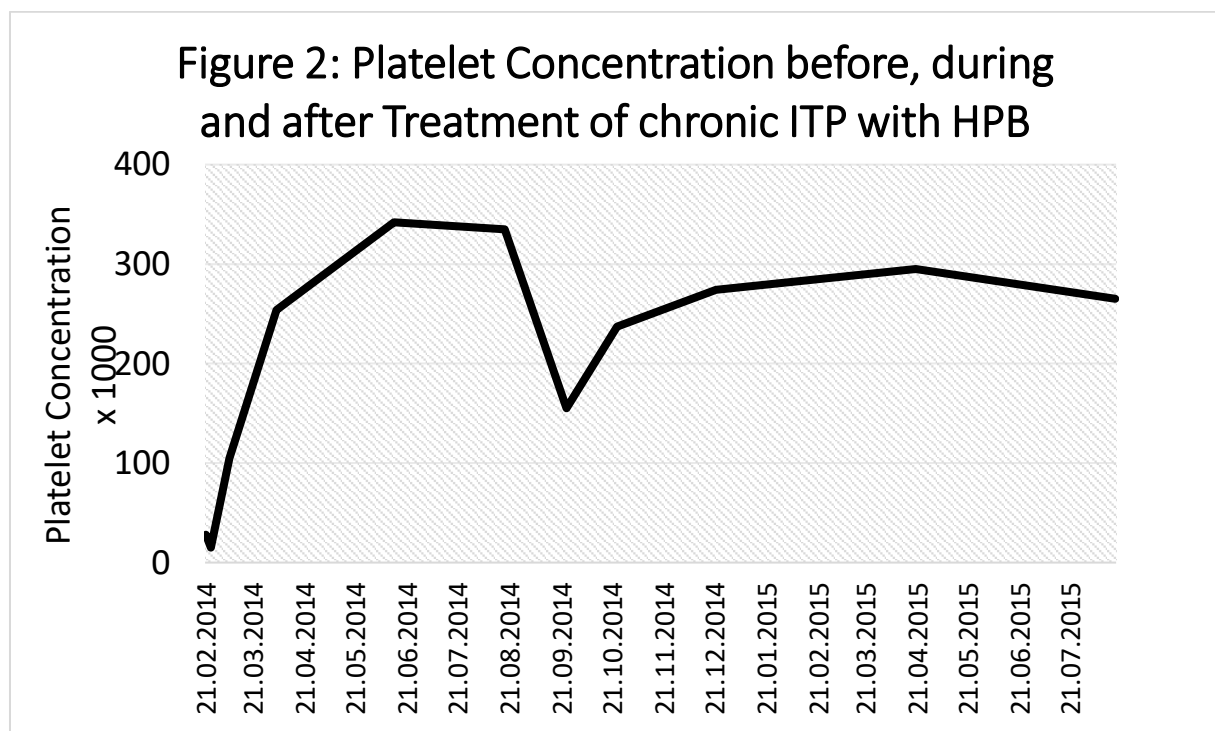


Figure 2: Platelet concentration in chronic ITP (x 1000/microliter) before, during, and after treatment with homeopathic dilutions of patient blood (HPB). The treatment ended on Aug. 18, 2014. Note the sharp decrease after treatment stop, as well as the following spontaneous recovery. (Dates on the x-axis are in the format DD/MM/YYYY).

Discussion

The steep increase in platelet concentration starting immediately after the initiation of treatment, as well as the decrease after its discontinuation, suggest a positive effect of homeopathic dilutions of patient blood. Due to the young age of the patient we consider a placebo effect rather improbable. The key question is whether the recovery was spontaneous or induced by treatment. In acute ITP a spontaneous remission occurs in 60% within the first month after diagnosis [6]. This probability is much smaller once the symptoms have lasted over six months, i.e. in chronic ITP. Rosthoi et al. observed a spontaneous recovery within 3 months in less than 5% of the children, and within 2 years in 35% of the children [7]. Similarly Coccia et al report a spontaneous remission rate of 42.8% within a period of 9 to 90 months, and calculate the probability of spontaneous remission of 24% at 4 years and 50% at 8 years [8]. The findings of other authors are similar [9,10,11]. From own experience in pediatric hematology we know, that spontaneous recovery of a chronic ITP is normally very slow, a gradual small increase in platelet concentration over many months, even years. What we saw in this patient is far beyond that: it rather resembles the increase seen after gammaglobulin treatment. - From a scientific point of view it would have been desirable to make an n = 1 study in this patient. We did not do it because the permissions needed would have delayed treatment for a timespan unacceptable to the parents.

The mode of action of homeopathic dilutions of patient blood in ITP is unclear. Imhäuser interprets their effect as immunomodulation, i.e. they moderate an overactive immune system or stimulate one that is too weak. Recent research by Chikramane et al. suggests that the homeopathic preparation of a substance leads to the formation of nanoparticles which retain molecules even in dilutions beyond the Avogadro constant [12]. If this hypothesis can be confirmed it would explain many phenomena observed in homeopathic treatment. There are ongoing efforts in Stuttgart and Bern to reproduce these results. In any case it is important not to draw the *false* conclusion that with an unknown mechanism of action there can be no effect.

Conclusion

Our pilot patient with chronic idiopathic thrombocytopenic purpura showed an outstanding and lasting normalization of platelet counts under oral treatment with a homeopathic dilution of her own blood. If the effect can be reproduced it would constitute a revolution in ITP treatment. The next step should be to study this treatment in a larger group of patients. We hope that this publication encourages other clinicians to adopt the idea of treating ITP with HPB, and report their experience to us. As a further step the treatment should be tested in a randomized control trial.

Disclosure Statement

The author has no commercial interests connected with this article.

Author

Heiner Frei, MD, Pediatrician FMH, Homeopathy SVHA

Kreuzplatz 6, CH-3177 Laupen, Switzerland

Email: heiner.frei@hin.ch

Tel: 0041 31 747 94 93

Fax: 0041 31 747 94 92

References

- 1 Mc Millan R: The pathogenesis of chronic immune thrombocytopenic purpura. *Semin Hematol* 2007; 44 (Suppl 5):3-11. DOI: [10.1053/j.seminhematol.2007.11.002](https://doi.org/10.1053/j.seminhematol.2007.11.002).
- 2 Zeller B, Rajantie J, Hedlund-Treutinger I, Tedgard U, Wesenberg F, Jonsson O, Henter JI, Rosthoi S: Childhood idiopathic thrombocytopenic purpura in Nordic countries: Epidemiology and predictors of chronic disease. *Acta Paediatrica* 2005;94(2):178-184.
- 3 Gousta B, Saberi Isfeedvajani M: An idiopathic thrombocytopenic purpura patient treated with homeopathy: a case report. *Hosp Pract Res* 2016;1(2):73-75.
- 4 Imhäuser H: *Homöopathie in der kinderärztlichen Praxis*, ed 13, Stuttgart, Haug, 2003.
- 5 Hahnemann S: *The organon of the medical art*, ed 6, 1842, reprint. Redmond, WA, Birdcage Books, 1996.
- 6 Kim H.C.: Childhood ITP. *Int J Hematol* 2002; 76 (Suppl 2):264. DOI:[10.1007/BF03165127](https://doi.org/10.1007/BF03165127).
- 7 Rosthoi S, Rajantie J, Treutiger I, Zeller B, Tedgard U, Henter JI, NOPHO ITP Working Group: Duration and morbidity of chronic immune thrombocytopenic purpura in children: five-year follow-up of a Nordic cohort. *Acta Paediatr* 2012;101(7):761-766. DOI:[10.1111/j.1651-2227.2012.02671](https://doi.org/10.1111/j.1651-2227.2012.02671).

- 8 Coccia P, Ruggiero A, Attina G, Cerchiara G, Battista A, Arena R, Scalzone M, Puma N, Ridola V, Riccardi R: Chronic idiopathic thrombocytopenic purpura in children: predictive factors and outcome. *Cent Eur J Med* 2012;7(4):525-528. DOI: [10.2478/s11536-012-0011-2](https://doi.org/10.2478/s11536-012-0011-2).
- 9 Donato H, Picon A, Martinez M, Rapetti MC, Rosso A, Gomez S: Splenectomy and spontaneous remission in children with chronic idiopathic thrombocytopenic purpura. *Pediatr Blood Cancer* 2006; 47 (5 Suppl):737-739.
- 10 Jayabose S, Levendoglu-Tugal O, Ozkaynak MF, Visintainer P, Sandoval C: Long-term outcome of chronic idiopathic thrombocytopenic purpura in children. *J Pediatr Hematol Oncol* 2004;26(11):724-726.
- 11 Aronis S, Platokouki H, Mitsika A, Haidas S, Constantopoulos A: Seventeen years of experience with chronic idiopathic thrombocytopenic purpura in childhood. Is therapy always better? *Pediatr Hematol Oncol* 1994; 11(5):487-498.
- 12 Chikramane PS, Suresh AK, Bellare JR, Kane SG: Extreme homeopathic dilutions retain starting materials: A nanoparticulate perspective. *Homeopathy* 2010;99 (4): 231-242.